

03/04/2018

IRB #17-0815-F2L

**University of Kentucky
College of Dentistry
Division of Periodontology**

**Ridge Preservation with Leukocyte Platelet Rich Fibrin: A Clinical, Radiographic, and
Histomorphometric Study**

Mhd firas Al Yafi, DDS

Committee Chair

Dr. Mohanad Al-Sabbagh

Committee Advisors

Dr. Dolphus Dawson

Dr. Galal Omami

Background and significance:

After a tooth extraction, the alveolar process loses a mean of 3.8 mm horizontally and 1.2 to 1.6 mm vertically, mostly within the first 3 months of healing.^{1,2} It loses up to 50% of its original dimension during the first year.³ This dramatic ridge resorption compromises prosthetically-driven implant placement. Resorption is more pronounced in the mandible than in the maxilla, and usually the buccal side loses more volume than the lingual.^{4,5} Alveolar ridge preservation has been used effectively to limit ridge reduction post tooth extraction.⁶⁻⁹ Current methods in socket grafting or ridge preservation include the use of autogenous grafts (graft from the same individual), allografts (graft from different individual of the same species), xenografts (graft from different species), and alloplasts (synthetic graft materials). These methods include naturally derived or synthetic, resorbable or non-resorbable membranes.¹⁰⁻¹² To date, the literature does not present clear guidelines for the type of bone graft material, membrane, or surgical procedure for ridge preservation.¹³

The use of the membrane prevents invagination of the epithelium, and gives the osteoblasts time and space to form new bone.^{4,14} The ideal membrane should be biocompatible, malleable, and able to exclude the soft tissue.^{15,16} In clinical studies, different types of barrier membranes have been used, with different rates of bone formation.^{4,5} Usually, resorbable and permeable synthetic membranes require tension free primary closure, which increases surgical complexity, reduces the amount of keratinized gingiva, disrupts the architecture of soft tissues, and compromises the vascularity of the flap with periosteal releasing incisions. The micro-porosity of high-density polytetrafluoroethylene (dPTFE) can exclude the bacteria and protect the graft even when exposed to the oral cavity.¹⁷ The successful use of (dPTFE) membrane has been demonstrated in animal and clinical trials.¹⁸⁻²⁰ Also, dPTFE membrane can be used predictably without a bone graft material to preserve the extraction sites.²¹

In a recent animal study, using autogenous bone particles does not have a significant effect in preventing ridge resorption²² while, xenografts maintain the dimensions of the ridge better compared to allografts alloplastic materials and natural healing. Sockets grafted with alloplastic materials (after >12 weeks) provide the highest amount of vital bone (45.5%), and the least amount of remnant graft material (13.7%), and connective tissue (38.4%), while, allograft

provided (30%, 21.7%, 51%), and xenograft provided (35.7%, 19.3%, 44.4%) respectively.²³ Some literature suggest that implant primary stability could be affected by the bone graft material remnants.²⁴

There is limited evidence to support the use of growth factors, human platelet-derived materials, platelet-rich fibrin, and stem cells as adjuncts to ridge preservation.²³ Leucocyte and platelet-rich fibrin (L-PRF) alone or in combination with a graft material can improve soft tissue healing, bone regeneration, ridge preservation, and reduces infection rate,²⁵⁻³⁰ L-PRF was introduced by Choukroun in 2001. L-PRF is composed of a dense high cross-linked fibrin mesh with the entrapped leucocytes and platelets, which in turn releases growth factors and cytokines for 7 days.^{31,32} Some investigators have reported a positive effect on bone regeneration^{33,34} while others failed to find any effect.³⁵ L-PRF outcomes for ridge preservation are comparable to those obtained with xenografts or allografts bone graft particulates, however, it is superior to alloplasts materials and natural healing. Use of L-PRF also provides additional advantages such as stimulating natural healing with patients own growth factors without any remnants and at a low cost.³⁶

The purpose of this clinical randomized study is to investigate the effect of L-PRF plug on the quality of newly formed bone in the preserved socket using non-resorbable membrane (d-PTFE).

Null hypothesis:

The use of L-PRF plug, in combination with non-resorbable, open barrier membrane technique to fill the extraction sockets will have no effect on the quality of the newly formed bone nor on the dimensional changes of the ridge, compared to non-resorbable, open barrier membrane technique with natural blood clot.

Alternative hypothesis:

The use of L-PRF plug, in combination with non-resorbable, open barrier membrane technique to fill the extraction sockets will have a positive effect on the quality of the newly formed bone and on preserving the dimensions of the alveolar ridge, compared to non-resorbable, open barrier membrane technique with natural blood clot.

Specific aims:

The primary aim is to assess the quality of the newly formed bone at the time of implant placement by comparing the percentage of new vital bone in the histomorphometric analysis. The second aim is to assess the primary stability of the implant using the resonance frequency analysis (RFA) and insertional torque (IT) of the implant. The third aim is to assess the horizontal and vertical changes of the residual bony ridge using Cone Beam Computerized Tomography (CBCT) analysis at baseline immediately after tooth extraction and prior to implant placement at 12 weeks of healing. The fourth aim is to assess the soft tissue healing with a series of intraoral occlusal photographs.

Material and methodsStudy Population

Forty-eight subjects will be recruited from the patient population of the University of Kentucky College of Dentistry clinics and will be randomly assigned into a control group and a test group by computer-generated randomization table. Following informed research consent, all subjects will complete a health history questionnaire. Twenty extraction socket sites of the test group will be filled with autogenous L-PRF Plug (Intralock®) and d-PTFE membrane (Cytoplast®) will be laid on the top to seal the extraction socket. In the control group, d-PTFE membrane (Cytoplast®) will be laid on the top of twenty extraction sockets to allow natural blood clot formation in the extraction socket. To account for expected attrition, an additional four patients will be recruited in each group.

Inclusion and exclusion criteria:

The subject must have an unsalvageable tooth that is planned for extraction and delayed implant placement. The tooth should be free of acute odontogenic infections, and only the extraction sockets with minimal to moderate bony defect will be included in the study.

Any patient who is planned for full mouth extraction, who is a heavy smoker (more than 10 cigarettes a day), who has a history of malignancy, chemotherapy, radiation therapy, immunosuppressive disease, uncontrolled systemic disease, or any contraindications to surgical procedures will be excluded from the study. Females who are pregnant or breastfeeding will be excluded as well. Also, for multi-rooted teeth, if the most coronal part of the interradicular septum is less than 5 mm below the crest of the bone, tooth will be excluded from the study.

Subject visits:

Screening Visit: All subjects will receive a comprehensive oral and periodontal examination. Patients who fulfill the inclusion criteria will continue in the study and will complete the baseline visit and all subsequent visits. After providing a thorough explanation about the study, an informed research consent will be obtained. The clinical examinations will be done on all patients by the same investigator throughout the study. If the patient is eligible, a pre-operative assessment and treatment planning will be done at this stage.

Visit 1 (Baseline): Tooth extraction, ridge preservation procedure, and CBCT will be performed. Autologous blood will be withdrawn and centrifuged to make the L-PRF plug in the test group. Intraoral occlusal photograph will be taken before and after tooth extraction.

Visit 2 (1-week from the baseline visit): Suture removal, and post-surgical follow-up evaluation will be performed and intraoral occlusal photograph will be taken.

Visit 3 (4-week from the baseline visit): Non-resorbable membrane will be removed and intraoral occlusal photograph will be taken.

Visit 4 (12-week from the baseline visit): A conventional or digital impression of the site will be taken and intraoral occlusal photograph will be taken. Then CBCT will be performed for implant planning.

Visit 5 (14-week from the baseline visit): A bone core biopsy will be performed and will be followed by the implant placement along with the primary stability assessment. Intraoral occlusal photographs will be taken before and after the surgery.

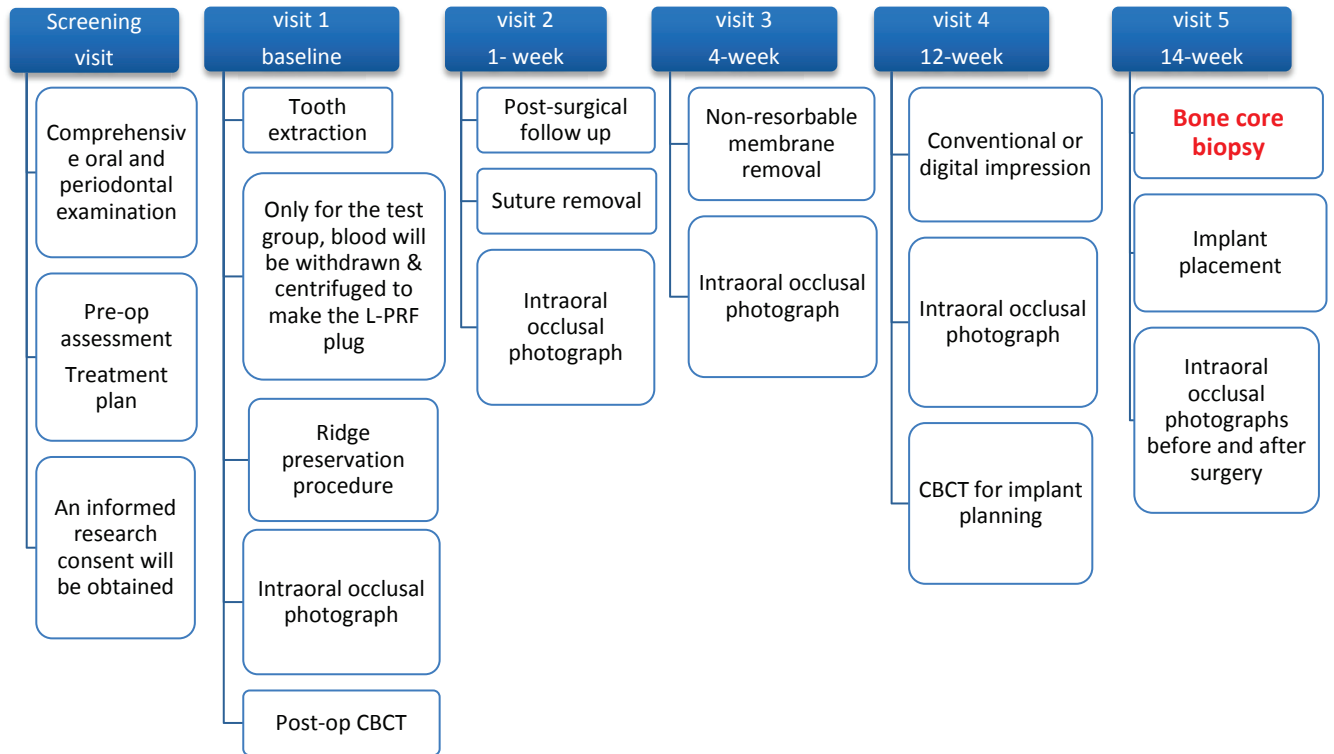


Table (1). Data collection for each visit of the study is described. All procedures described above are Standard of Care except bone core biopsy in visit 5 is a research components.

Intraoral occlusal photograph:

Intraoral photograph will be taken to evaluate soft tissue healing. Standardization of photographs will be tried by using an occlusal mirror with a 40° angle to the occlusal plane of a patient in a supine position. Fixed camera settings will be used in all sessions. Photos will be taken at the base line, 1-week, 4-week, 12-week and 14-week visits.

L-PRF plug preparation Protocol:³⁷

A venipuncture with a 21 Gauge butterfly needle will be used to collect up to six 9 ml tubes of blood. Tubes immediately are placed into the IntraSpin™ centrifuge, and counterbalanced with each other. Centrifugation will be run at 2700 rpm for 12 minutes, however, in patient taking anti-coagulant medication up to 18 minutes are recommended. The centrifugation would separate the red blood cells layer at the bottom, the platelet poor plasma layer on the top, and the L-PRF fibrin clot in the middle of the tubes. Fibrin clots will be taken out of the tubes and then will be placed in the small white cylinder of the Xpression™ box, and compressed until holder is level to cylinder. The plugs stay viable up to 3 hours, if they are re-hydrated with the PRF exudate.

Ridge preservation surgical Procedure:

After administration of the local anesthetic (LA), full thickness buccal and lingual flaps will be elevated about 3-4 mm pass the socket bone crest. Atraumatic tooth extraction will be performed using peizosurgery, periotomes and/or elevators with root sectioning on multi-rooted teeth. The socket will be curreted, then copious saline irrigation will be applied. The extraction sockets of the test group will be filled up to the crest of the ridge with 3-5 L-PRF Plugs, depending on the size of the socket, and condensed with the amalgam condensor. A d-PTFE membrane (Cytoplast®) will be laid on the top of the extraction socket of test and control group and will be inserted 3-4 mm beyond the bone crest. Flap will be re-positioned to its original position with no attempt to get primary closure for either group.

Implant digital surgical guide

A digital or conventional impression of the site will be taken to obtain an STL file, and a DICOM file from the CBCT at 12-week visit. Then surgical guide will be fabricated (Dreve®) utilizing the coDiagnostiX™ software in order to plan for the future implant size and location in a prosthetic driven manner. The same guide will be used for the bone core sample, with a trephine bur of a suitable size.

Implant placement surgical Procedure:

Using the implant surgical guide a core bone biopsy will be taken from the healed extraction site. Then the implant will be placed as recommended by the manufacturer (BLT, Straumann®), and additional bone grafting will be done if needed. The implant stability quotient (ISQ), and insertional torque (IT) will be recorded at the implant placement time to assess the primary stability.

Pre- and Post- operative instructions:

Prophylaxis Antibiotics: Standard of care Amoxicillin 2 g will be given one hour prior to surgery or Clindamycin 600 mg one hour prior to surgery if the subject is reported to be allergic to Penicillin.

Analgesic: NSAID will be prescribed as needed. Patient will be instructed to use Chlorhexidine 0.12% mouth rinse twice a day for five weeks. The patient will be instructed to be refrained from brushing or flossing to the surgical site for 10 days.

Histomorphometric assessment:

The core bone biopsy will be harvested using the surgical implant guide at the time of implant placement. It will be placed in a container with 10% neutral buffered formalin. The sample will be sent for light microscopy histologic slides preparation in the lab. The bone specimens will be demineralized in EDTA for a month and embedded in paraffin wax. Bone sections (~5µm) will be obtained using the Leica (RM 2255, Leica, IL) microtome. For each biopsy specimen, longitudinal section will be used for light microscopic examination. Histomorphometric analysis will be performed on three fields for each section using specialized software (Bioquant, Nashville, TN). Percentages of newly formed bone, residual connective tissue, and any material remnants will be measured based on the averages of the percentages at a magnification of 100X.

CBCT acquisition:

CBCT images^{38, 39} will be acquired by i-CAT FLX Cone Beam 3D system (Imaging Sciences, Hatfield, PA, USA) at baseline immediately after tooth extraction, and prior to implant placement at 12 weeks post extraction. Scans will be obtained at the Standard protocol (360° rotation, 300 frames, 120 kVp, 5 mA, 3.7 sec, 16 x 8 cm FOV, 400 µm voxel size).

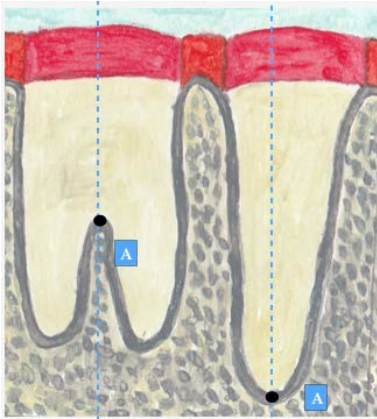
CBCT analysis²⁶

The analysis of the CBCTs will be performed according to the analysis described by Jung et al. (2013). To perform the CBCT measurements, scans taken immediately after extraction (CBCT 0), will be superimposed on scans taken at 12 weeks post extraction (CBCT 12) using InVivo 5.2 imaging software (Anatomage, San Jose, CA, USA). For the superimposition of the cross-sectional slices, the fixed anatomical landmarks include the palatal vault in the maxilla, the lower border and angle in the mandible, where no changes would occur after extraction. Both data sets would be spatially aligned in order to obtain a match. To set a reference, in single-rooted teeth, the most apical point (A) of the extraction socket is defined in the baseline image (CBCT 0), while in the multi-rooted teeth point (A) to be the most coronal point on the interradiacal septum, right at the center of the extraction socket (Fig 1). Two reference lines are subsequently drawn. The vertical reference line is drawn in the center of the extraction socket crossing (A) reference point. The horizontal reference line is drawn perpendicular to the vertical line crossing the apical reference point (Fig 2).

The following measurements are then performed (Fig. 3):

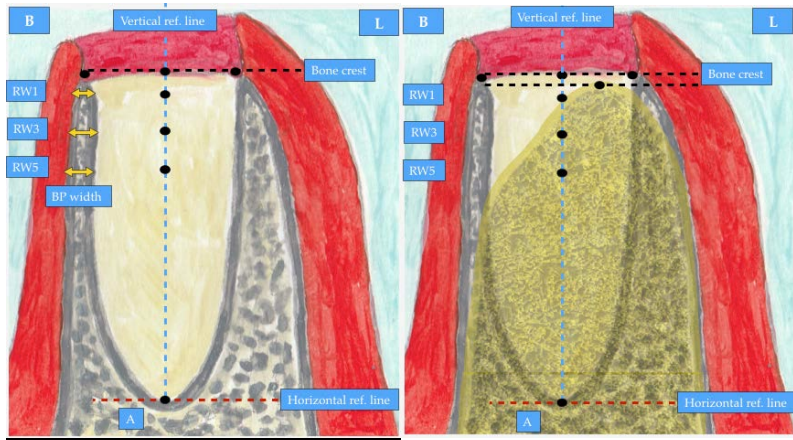
1. The thickness of the buccal plate (BP) on CBCT0 will be measured at 1, 3 & 5 mm below the lingual bone crest.
2. Horizontal ridge width (RW) will be measured at 3 levels: 1,3,5 mm below the buccal bone crest.
3. Vertical resorption of both the buccal and lingual plates will be measured in millimeter.
4. Socket fill percentage will be assessed based on the highest point of viewable mineralized bone on CBCT12.

Primary outcome variable is socket fill with new bone. Secondary outcome variables are changes in horizontal width at crest -1mm, 3 mm, and 5 mm levels; and vertical resorption at the lingual and buccal side.



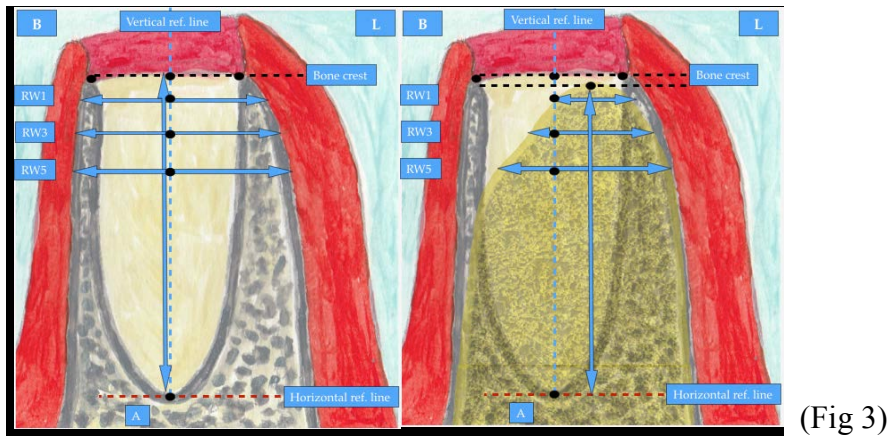
(Fig 1)

Figure 1. In single-rooted teeth the most apical point (A) of the extraction socket is defined in the baseline image (CBCT 0), while in the multi-rooted teeth point (A) to be the most coronal point on the septum, right at the center of the extraction socket.



(Fig 2)

Figure 2. Two reference lines are subsequently drawn. The vertical reference line (the blue interrupted line) is drawn in the center of the extraction socket crossing the apical reference point. The horizontal reference line (the red interrupted line) is drawn perpendicular to the vertical line crossing the apical reference point.



(Fig 3)

Figure 3. Following measurements are then performed:

1. The thickness of the buccal bone plate is to be measured at 1, 3 & 5 mm below the lingual bone crest (PB Width), on baseline image only.
2. Horizontal ridge width at 3 levels (crest -1 mm (RW-1 mm), crest -3 mm (RW-3 mm) & crest -5 mm (RW-5 mm)) below the most coronal point of the buccal crest, in millimeter.
3. Vertical resorption on both the buccal and palatal side, in millimeter.
4. Socket fill as being the highest point of viewable mineralized bone. Percentages of socket fill will be measured by comparing the initial depth of the socket and the depth after 12 weeks of healing.

Adverse Effects:

If patients experience pain that cannot be managed by the prescribed analgesic, they will be told to contact the principal investigator for follow-up.

The membrane will be left on the extraction socket for 4 weeks, if there is no sign of infection, otherwise any infection will be treated which may necessitate the removal of membrane.

Subjects will be monitored for other adverse reactions throughout the study. All adverse events will be managed and documented by the principal investigator.

Statistical Analysis:

For the expected result, A sample size of 20 in each group will have at least 80% power to detect an effect size (ES) of 0.9 using a two groups t-test with a 0.050 two-sided significance level. The t-test will be used for the histomorphometric analysis, ISQ and, insertional torque. While, Manova will be used for the CBCT multiple measurements.

Subject incentives will consist of 50\$ Gift card, and a free follow up CBCT after completion of visit 5.

References:

1. Tan WL, Wong TL, Wong MC, Lang NP. A systematic review of post-extraction alveolar hard and soft tissue dimensional changes in humans. *Clin Oral Implants Res* 2012;23 Suppl 5:1-21.
2. Van der Weijden F, Dell'Acqua F, Slot DE. Alveolar bone dimensional changes of post-extraction sockets in humans: a systematic review. *J Clin Periodontol* 2009;36:1048-1058.
3. Schropp L, Wenzel A, Kostopoulos L, Karring T. Bone healing and soft tissue contour changes following single-tooth extraction: a clinical and radiographic 12-month prospective study. *Int J Periodontics Restorative Dent* 2003;23:313-323.
4. Smukler H, Landi L, Setayesh R. Histomorphometric evaluation of extraction sockets and deficient alveolar ridges treated with allograft and barrier membrane: a pilot study. *Int J Oral Maxillofac Implants* 1999;14:407-416.
5. Fotek PD, Neiva RF, Wang HL. Comparison of dermal matrix and polytetrafluoroethylene membrane for socket bone augmentation: a clinical and histologic study. *J Periodontol* 2009;80:776-785.
6. Friedmann A, Strietzel FP, Marezki B, Pitaru S, Bernimoulin JP. Histological assessment of augmented jaw bone utilizing a new collagen barrier membrane compared to a standard barrier membrane to protect a granular bone substitute material. *Clin Oral Implants Res* 2002;13:587-594.
7. Wang HL, Tsao YP. Histologic evaluation of socket augmentation with mineralized human allograft. *Int J Periodontics Restorative Dent* 2008;28:231-237.
8. Avila-Ortiz G, Elangovan S, Kramer KW, Blanchette D, Dawson DV. Effect of alveolar ridge preservation after tooth extraction: a systematic review and meta-analysis. *J Dent Res* 2014;93:950-958.
9. Ten Heggeler JM, Slot DE, Van der Weijden GA. Effect of socket preservation therapies following tooth extraction in non-molar regions in humans: a systematic review. *Clin Oral Implants Res* 2011;22:779-788.
10. Barteck BK. Extraction site reconstruction for alveolar ridge preservation. Part 2: membrane-assisted surgical technique. *J Oral Implantol* 2001;27:194-197.
11. Iasella JM, Greenwell H, Miller RL, et al. Ridge preservation with freeze-dried bone allograft and a collagen membrane compared to extraction alone for implant site development: a clinical and histologic study in humans. *J Periodontol* 2003;74:990-999.
12. Laney WR. Glossary of Oral and Maxillofacial Implants. *Int J Oral Maxillofac Implants* 2017;32:G1-G200.
13. Vignoletti F, Matesanz P, Rodrigo D, Figuero E, Martin C, Sanz M. Surgical protocols for ridge preservation after tooth extraction. A systematic review. *Clin Oral Implants Res* 2012;23 Suppl 5:22-38.
14. Schenk RK, Buser D, Hardwick WR, Dahlin C. Healing pattern of bone regeneration in membrane-protected defects: a histologic study in the canine mandible. *Int J Oral Maxillofac Implants* 1994;9:13-29.
15. Scantlebury TV. 1982-1992: a decade of technology development for guided tissue regeneration. *J Periodontol* 1993;64:1129-1137.
16. Rakhmatia YD, Ayukawa Y, Furuhashi A, Koyano K. Current barrier membranes: titanium mesh and other membranes for guided bone regeneration in dental applications. *J Prosthodont Res* 2013;57:3-14.
17. Barteck BK. The use of high-density polytetrafluoroethylene membrane to treat osseous defects: clinical reports. *Implant Dent* 1995;4:21-26.

18. Bartee BK, Carr JA. Evaluation of a high-density polytetrafluoroethylene (n-PTFE) membrane as a barrier material to facilitate guided bone regeneration in the rat mandible. *J Oral Implantol* 1995;21:88-95.
19. Crump TB, Rivera-Hidalgo F, Harrison JW, Williams FE, Guo IY. Influence of three membrane types on healing of bone defects. *Oral Surg Oral Med Oral Pathol Oral Radiol Endod* 1996;82:365-374.
20. Walters SP, Greenwell H, Hill M, Drisko C, Pickman K, Scheetz JP. Comparison of porous and non-porous teflon membranes plus a xenograft in the treatment of vertical osseous defects: a clinical reentry study. *J Periodontol* 2003;74:1161-1168.
21. Hoffmann O, Bartee BK, Beaumont C, Kasaj A, Deli G, Zafiroopoulos GG. Alveolar bone preservation in extraction sockets using non-resorbable dPTFE membranes: a retrospective non-randomized study. *J Periodontol* 2008;79:1355-1369.
22. Araujo MG, Lindhe J. Socket grafting with the use of autologous bone: an experimental study in the dog. *Clin Oral Implants Res* 2011;22:9-13.
23. Jambhekar S, Kernen F, Bidra AS. Clinical and histologic outcomes of socket grafting after flapless tooth extraction: a systematic review of randomized controlled clinical trials. *J Prosthet Dent* 2015;113:371-382.
24. Marquezan M, Osorio A, Sant'Anna E, Souza MM, Maia L. Does bone mineral density influence the primary stability of dental implants? A systematic review. *Clin Oral Implants Res* 2012;23:767-774.
25. Miron RJ, Zucchelli G, Pikos MA, et al. Use of platelet-rich fibrin in regenerative dentistry: a systematic review. *Clin Oral Investig* 2017;21:1913-1927.
26. Temmerman A, Vandessel J, Castro A, et al. The use of leucocyte and platelet-rich fibrin in socket management and ridge preservation: a split-mouth, randomized, controlled clinical trial. *J Clin Periodontol* 2016;43:990-999.
27. Castro AB, Meschi N, Temmerman A, et al. Regenerative potential of leucocyte- and platelet-rich fibrin. Part B: sinus floor elevation, alveolar ridge preservation and implant therapy. A systematic review. *J Clin Periodontol* 2017;44:225-234.
28. Singh A, Kohli M, Gupta N. Platelet rich fibrin: a novel approach for osseous regeneration. *J Maxillofac Oral Surg* 2012;11:430-434.
29. Hauser F, Gaydarov N, Badoud I, Vazquez L, Bernard JP, Ammann P. Clinical and histological evaluation of postextraction platelet-rich fibrin socket filling: a prospective randomized controlled study. *Implant Dent* 2013;22:295-303.
30. Kumar N, Prasad K, Ramanujam L, K R, Dexith J, Chauhan A. Evaluation of treatment outcome after impacted mandibular third molar surgery with the use of autologous platelet-rich fibrin: a randomized controlled clinical study. *J Oral Maxillofac Surg* 2015;73:1042-1049.
31. Dohan DM, Choukroun J, Diss A, et al. Platelet-rich fibrin (PRF): a second-generation platelet concentrate. Part III: leucocyte activation: a new feature for platelet concentrates? *Oral Surg Oral Med Oral Pathol Oral Radiol Endod* 2006;101:e51-55.
32. Roy S, Driggs J, Elgharably H, et al. Platelet-rich fibrin matrix improves wound angiogenesis via inducing endothelial cell proliferation. *Wound Repair Regen* 2011;19:753-766.
33. Ozdemir H, Ezirganli S, Isa Kara M, Mihmanli A, Baris E. Effects of platelet rich fibrin alone used with rigid titanium barrier. *Arch Oral Biol* 2013;58:537-544.
34. Pradeep AR, Rao NS, Agarwal E, Bajaj P, Kumari M, Naik SB. Comparative evaluation of autologous platelet-rich fibrin and platelet-rich plasma in the treatment of 3-wall intrabony defects in chronic periodontitis: a randomized controlled clinical trial. *J Periodontol* 2012;83:1499-1507.
35. Zhang Y, Tangl S, Huber CD, Lin Y, Qiu L, Rausch-Fan X. Effects of Choukroun's platelet-rich fibrin on bone regeneration in combination with deproteinized bovine bone mineral in maxillary sinus

- augmentation: a histological and histomorphometric study. *J Craniomaxillofac Surg* 2012;40:321-328.
36. Anwandter A, Bohmann S, Nally M, Castro AB, Quirynen M, Pinto N. Dimensional changes of the post extraction alveolar ridge, preserved with Leukocyte- and Platelet Rich Fibrin: A clinical pilot study. *J Dent* 2016;52:23-29.
 37. Pinto N TA, Teughels W, Castro A, Cortellini S, Quirynen M Consensus Guidelines on the Use of L-PRF from the 1st European Meeting on Enhanced Natural Healing in Dentistry. 2016.
 38. Tyndall DA, Price JB, Tetradis S, et al. Position statement of the American Academy of Oral and Maxillofacial Radiology on selection criteria for the use of radiology in dental implantology with emphasis on cone beam computed tomography. *Oral Surg Oral Med Oral Pathol Oral Radiol* 2012;113:817-826.
 39. Benic GI, Elmasry M, Hammerle CH. Novel digital imaging techniques to assess the outcome in oral rehabilitation with dental implants: a narrative review. *Clin Oral Implants Res* 2015;26 Suppl 11:86-96.

Combined Consent and Authorization to Participate in a Research Study

Ridge Preservation with Leukocyte Platelet Rich Fibrin: A Clinical, Radiographic, and Histomorphometric Study

WHY ARE YOU BEING INVITED TO TAKE PART IN THIS RESEARCH?

You are being invited to take part in a research study about post tooth extraction ridge preservation with platelet rich fibrin. You are being invited to take part in this research study because you need to have a non-restorable tooth that is planned for extraction and delayed implant placement. If you volunteer to take part in this study, you will be one of about forty people at the University of Kentucky College of Dentistry to do so.

WHO IS DOING THE STUDY?

The person in charge of this study is Mhdfiras Al Yafi DDS, resident at the University of Kentucky, Department of Periodontics. He is being guided in this research by Mohanad Al-Sabbagh DDS MS, Periodontics Division Chief. There may be other people on the research team assisting at different times during the study.

WHAT IS THE PURPOSE OF THIS STUDY?

The focus of this research is to see how much the use of Leukocyte- Platelet Rich Fibrin Plug in the ridge preservation procedure following a tooth extraction will improve the quality of the newly formed bone in the extraction socket. By doing this, we hope to find the best way to prevent the bone loss after tooth extraction.

ARE THERE REASONS WHY YOU SHOULD NOT TAKE PART IN THIS STUDY?

If you are a heavy smoker (more than 10 cigarettes a day), have a history of malignancy, chemotherapy, radiation therapy, immunosuppressive disease, uncontrolled systemic disease, or any contraindications to surgical procedures, you should not participate in the study. Also, females who are pregnant or breastfeeding should not take part in this study. Also, for multi-rooted teeth, if the most coronal part of the interradicular septum is less than 5 mm below the crest of the bone, tooth will be excluded from the study.

WHERE IS THE STUDY GOING TO TAKE PLACE AND HOW LONG WILL IT LAST?

The research procedures will be conducted at UK College of Dentistry Periodontics Clinic. You will need to come to Graduate Periodontics' clinic at the fourth floor, for 5 visits for a total of 300 minutes during the next 14 weeks. The expected time of each visits will be as following:

- Visit 1: 60-90 minutes.
- Visit 2: 15-30 minutes.
- Visit 3: 15-30 minutes.
- Visit 4: 30-60 minutes.
- Visit 5: 60-90 minutes.

WHAT WILL YOU BE ASKED TO DO?

At visit 1 (Baseline): by chance you will be randomized to one of two groups: for the first group after applying local anesthetic tooth will be extracted then a non-resorbable membrane will be used to preserve the ridge, While, for the second group after applying local anesthetic tooth extraction will be followed by the collection of about 50 ml. of the patient's venous blood, the blood will be spun to make a plug which will be packed in the extraction socket then a non-resorbable membrane will be used to preserve the ridge.

CBCT will be performed and Intraoral photographs will be taken before and after tooth extraction for the both groups.

At visit 2 (1-week from the baseline visit): Suture removal, and post-surgical follow-up evaluation will be performed and an intraoral photograph will be taken.

At visit 3 (4-week from the baseline visit): the membrane will be removed and an intraoral photograph will be taken.

At visit 4 (12-week from the baseline visit): An impression of the teeth, A CBCT will be performed, and an intraoral photograph will be taken.

At visit 5 (14-week from the baseline visit): A bone core biopsy will be performed and will be followed by the implant placement. Also, intraoral photographs will be taken before and after the procedure.

All procedures described above are standard of care except bone core biopsy in visit 5 is for research. The average CBCT radiation dose for the used setting is 45 μ Sv, which is equivalent to 6 days of US Per capita background radiation.

WHAT ARE THE POSSIBLE RISKS AND DISCOMFORTS?

Although this study has a minimal risk, in rare instance, you might experience pain that cannot be managed by the prescribed analgesic. Also, the membrane on the extraction socket will be left exposed to your mouth for 4 weeks. occasionally if you are not cleaning the membrane well, this might necessitate the removal of membrane. If you were assigned to the second group where the venipuncture is being performed, complications that can arise include *soreness, bruising, pain, infection, possible fainting, bleeding.*

There is always a chance that any surgical procedure can have some complications, such as post-surgical bleeding, soreness, pain, bruising or infection. and the treatment in this study is no different. In addition to the risks listed above, you may experience a previously unknown risk or side effect.

The radiation dose from a typical dental x-ray is about 1/40th of the typical natural background radiation dose that we all receive every year. It is also about 1/7th of the annual safe dose limit dose (not including medical exposures) for members of the public and well below the levels that are considered to be a significant risk of any harmful effects.

However, you should contact the principal investigator for follow-up and complications management.

Possible Risk/Side Effect	How often has it occurred?	How serious is it?	Can it be corrected?
After surgery discomfort	Common	Usually of short duration. Not serious	Yes
Prolonged or heavy bleeding	Uncommon	In otherwise healthy patients, it causes discomfort. Not serious	Yes
Bruising (greenish-yellow to black and blue color)	Uncommon	It will not impact overall health. Not serious	Yes
Injury to the crown, roots, or fillings of adjacent teeth	Very uncommon	Depends on the extent of injury. Not serious	Correction depends on the severity of the injury
After treatment infection, cracking and/or bruising of lips due to stretching of corners of the mouth)	Common for the posterior regions	Patients discomfort. Not serious	Yes
Limited mouth opening during healing (sometimes related to swelling and muscle soreness, and sometimes related to stress on jaw joints (TMJ), especially with pre-existing TMJ problems)	Uncommon	Patient discomfort. Not serious	Yes
Allergic reactions to any medications used in treatment	Very uncommon	Serious in some allergy reactions	Yes
Injury to nerves in tissues surrounding teeth	Very uncommon	Serious pain, numbness, tingling or other sensory disturbances in the chin, lip, cheek, gums, or tongue. Serious	May persist for several months or in rare instances permanently
Complications for venipuncture	Common	Usually of short duration. Not serious	Yes

WILL YOU BENEFIT FROM TAKING PART IN THIS STUDY?

There is no guarantee that you will get any benefit from taking part in this study. Your willingness to take part, however, may, in the future, help doctors better understand and treat others who have your condition.

DO YOU HAVE TO TAKE PART IN THE STUDY?

If you decide to take part in the study, it should be because you really want to volunteer. You will not lose any benefits or rights you would normally have if you choose not to volunteer. You can stop at any time during the study and still keep the benefits and rights you had before volunteering. If you decide not to take part in this study, your decision will have no effect on the quality of medical care you receive.

IF YOU DON'T WANT TO TAKE PART IN THE STUDY, ARE THERE OTHER CHOICES?

If you do not want to take part in the study, there are other choices such as tooth extraction with immediate implant placement, and fixed or removable prosthesis. And any treatment option that is not included in the research will be at your own cost.

WHAT WILL IT COST YOU TO PARTICIPATE?

The University of Kentucky may not be allowed to bill your insurance company, Medicare or Medicaid for the medical procedures done strictly for research. However, you will not be charged for the bone core biopsy procedure in visit 5 or any additional medical procedures done strictly for research. You and/or your insurance company, Medicare or Medicaid will be responsible for the costs of all care and treatment you receive during this study that you would normally receive for your condition. These are costs that are considered medically reasonable and necessary and will be part of the care you receive if you do not take part in this study.

A co-payment/deductible from you may be required by your insurer or Medicare/Medicaid even if your insurer or Medicare/Medicaid has agreed to pay the costs. The amount of this co-payment/deductible may be substantial. If you have any questions regarding Medicare/Medicaid coverage you should contact Medicare by calling 1-800-Medicare (1-800-633-4227) or Medicaid at 1-800-635-2570).

WHO WILL SEE THE INFORMATION THAT YOU GIVE?

We will make every effort to keep confidential all research records that identify you to the extent allowed by law.

Your information will be combined with information from other people taking part in the study. When we write about the study to share it with other researchers, we will write about the combined information we have gathered. You will not be personally identified in these written materials. We may publish the results of this study; however, we will keep your name and other identifying information private. However, Officials of the Food and Drug Administration and the University of Kentucky may look at or copy pertinent portions of records that identify you.

We will make every effort to prevent anyone who is not on the research team from knowing that you gave us information, or what that information is. Only the study Principal investigator, Mhdfiras Al Yafi will have access to your identifying information.

You should know, however, that there are some circumstances in which we may have to show your information to other people. For example, the law may require us to show your information to a court or to tell authorities if you report information about a child being abused or if you pose a danger to yourself or someone else.

CAN YOUR TAKING PART IN THE STUDY END EARLY?

If you decide to take part in the study you still have the right to decide at any time that you no longer want to continue. You will not be treated differently if you decide to stop taking part in the study. However, if you choose to withdraw from the study early, the data collected until that point will remain in the study database and may not be removed.

ARE YOU PARTICIPATING OR CAN YOU PARTICIPATE IN ANOTHER RESEARCH STUDY AT THE SAME TIME AS PARTICIPATING IN THIS ONE?

You may take part in this study if you are currently involved in another research study. It is important to let the investigator/your doctor know if you are in another research study. You should also discuss with the investigator before you agree to participate in another research study while you are enrolled in this study.

WHAT HAPPENS IF YOU GET HURT OR SICK DURING THE STUDY?

If you believe you are hurt or if you get sick because of something that is due to the study, you should call Mhdfiras Al Yafi DDS, PI at 859-323-6193 or Mohanad Al-Sabbagh DDS MS, Periodontics Division Chief at 859-323-5831 immediately.

It is important for you to understand that the University of Kentucky does not have funds set aside to pay for the cost of any care or treatment that might be necessary because you get hurt or sick while taking part in this study. Also, the University of Kentucky will not pay for any wages you may lose if you are harmed by this study.

The medical costs related to your care and treatment because of research related harm will be your responsibility.

You do not give up your legal rights by signing this form.

WILL YOU RECEIVE ANY REWARDS FOR TAKING PART IN THIS STUDY?

You will receive a \$50 Gift card upon the completion of all visits for taking part in this study.

WHAT IF YOU HAVE QUESTIONS, SUGGESTIONS, CONCERNS, OR COMPLAINTS?

Before you decide whether to accept this invitation to take part in the study, please ask any questions that might come to mind now. Later, if you have questions, suggestions, concerns, or complaints about the study, you can contact the investigator, Mhdfiras Al Yafi DDS at 859-323-6193. If you have any questions about your rights as a volunteer in this research, contact the staff in the Office of Research Integrity at the University of Kentucky between the business hours of 8am and 5pm EST, Mon-Fri at 859-257-9428 or toll free at 1-866-400-9428. We will give you a signed copy of this consent form to take with you.

WHAT IF NEW INFORMATION IS LEARNED DURING THE STUDY THAT MIGHT AFFECT YOUR DECISION TO PARTICIPATE?

If the researcher learns of new information in regard to this study, and it might change your willingness to stay in this study, the information will be provided to you. You may be asked to sign a new informed consent form if the information is provided to you after you have joined the study.

WHAT ELSE DO YOU NEED TO KNOW?

There is a possibility that the data/tissue/specimens collected from you may be shared with other investigators in the future. If that is the case the data/tissue/specimen will not contain information that can identify you unless you give your consent/authorization or the UK Institutional Review Board (IRB) approves the research. The IRB is a committee that reviews ethical issues, according to federal, state and local regulations on research with human subjects, to make sure the study complies with these before approval of a research study is issued.

A description of this clinical trial will be available on <http://www.ClinicalTrials.gov> as required by U.S. Law. This website will not include information that can identify you. At most, the website will include a summary of the results. You can search this website at any time.

AUTHORIZATION TO USE OR DISCLOSE YOUR IDENTIFIABLE HEALTH INFORMATION

The privacy law, HIPAA (Health Insurance Portability and Accountability Act), requires researchers to protect your health information. The following sections of the form describe how researchers may use your health information.

Your health information that may be accessed, used and/or released includes:

Your demographic information, results of physical exams, *X-rays, medical history and other diagnostic and medical procedures including:*

- *CBCT's report and findings.*
- *Histomorphometric analysis results.*
- *Intraoral photographs.*

Also include Medicare Health Insurance Claim Numbers (HICN), Social Security Numbers (SSN).

The Researchers may use and share your health information with:

- The University of Kentucky's Institutional Review Board/Office of Research Integrity.
- Law enforcement agencies when required by law.
- University of Kentucky representatives.
- Primary physician will be contacted if researcher in the course of the project learns of a medical condition that needs immediate attention.
- *The Food and Drug Administration (FDA).*

The researchers agree to only share your health information with the people listed in this document.

Should your health information be released to anyone that is not regulated by the privacy law, your health information may be shared with others without your permission; however, the use of your health information would still be regulated by applicable federal and state laws.

You may not be allowed to participate in the research study if you do not sign this form. If you decide not to sign the form, it will not affect your:

- **Current or future healthcare at the University of Kentucky**
- **Current or future payments to the University of Kentucky**
- **Ability to enroll in any health plans (if applicable)**
- **Eligibility for benefits (if applicable)**

After signing the form, you can change your mind and NOT let the researcher(s) collect or release your health information (revoke the Authorization). If you revoke the authorization:

- You will send a written letter to: the investigator, Mhdfiras Al Yafi DDS at University of Kentucky College of Dentistry / Oral Health Practice Department, 4th Floor Dental Science Bldg. 800 Rose St. 40536-0297. Or call at 859-323-6193 to inform *him* of your decision.
- Researchers may use and release your health information **already** collected for this research study.
- Your protected health information may still be used and released should you have a bad reaction (adverse event).

The use and sharing of your information has no time limit.

If you have not already received a copy of the Privacy Notice, you may request one. If you have any questions about your privacy rights, you should contact the University of Kentucky's Privacy Officer between the business hours of 8am and 5pm EST, Mon-Fri at: (859) 323-1184.

You are the subject or are authorized to act on behalf of the subject. You have read this information, and you will receive a copy of this form after it is signed.

Signature of research subject

Date

Printed name of research subject

Name of [authorized] person obtaining informed consent/HIPAA authorization

Date

Signature of Principal Investigator or Sub/Co-Investigator